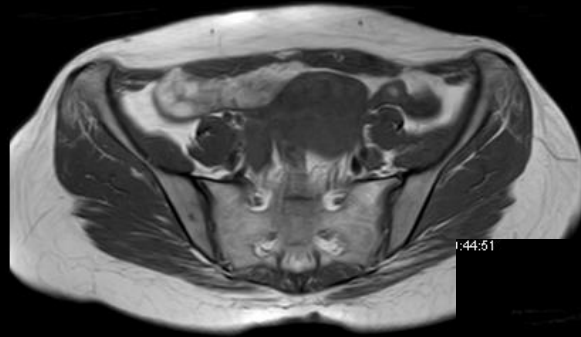
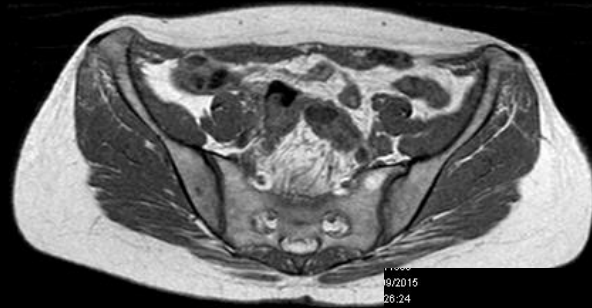

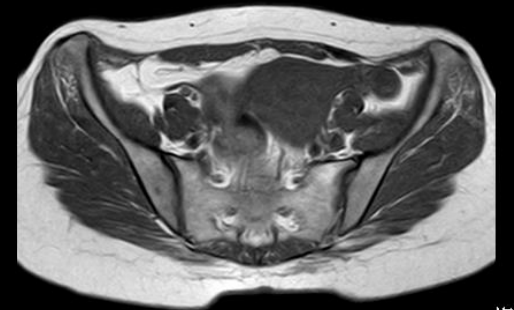
Sep 2013



Feb 2014



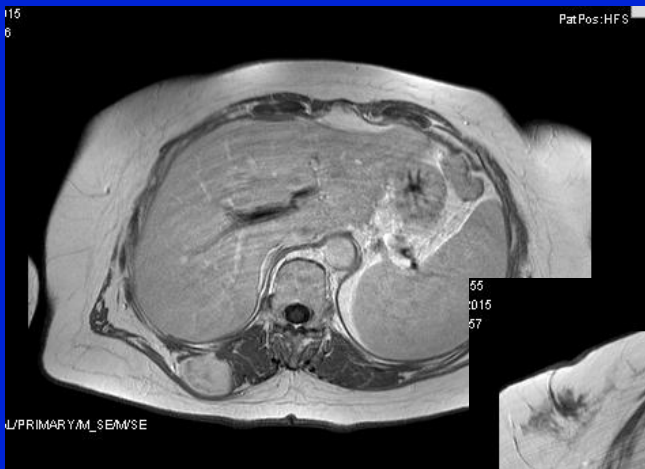
Gen 2015



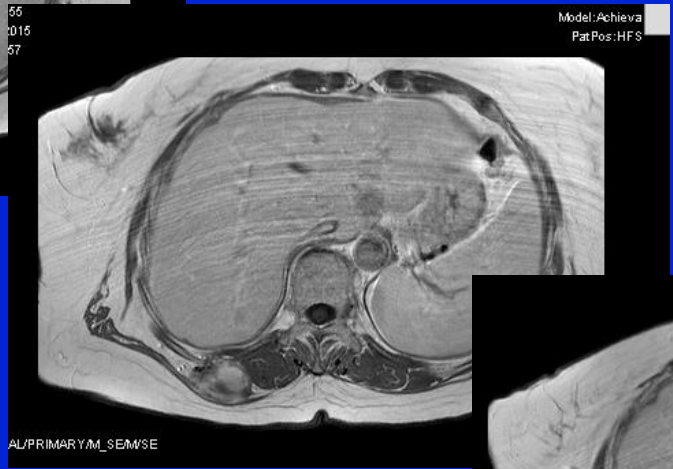Sep 2015

Female
48 yrs old
Abdominal wall
Initial size: 5 cm
Time to complete regression:
24 months

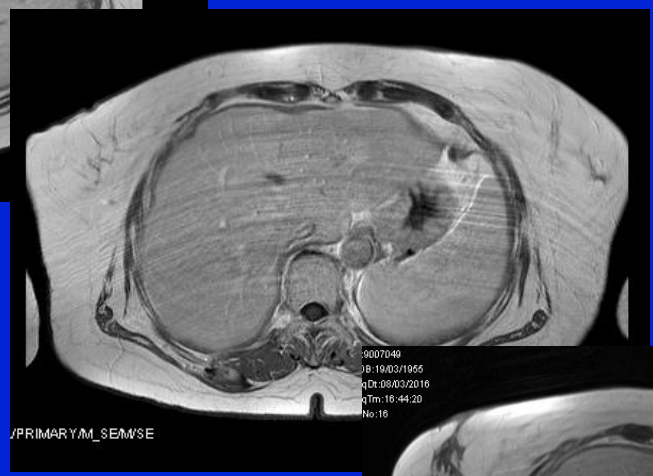




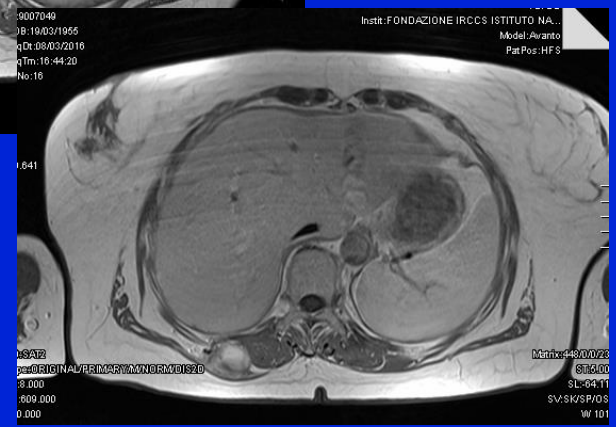
Ago 2015



Dic 2015



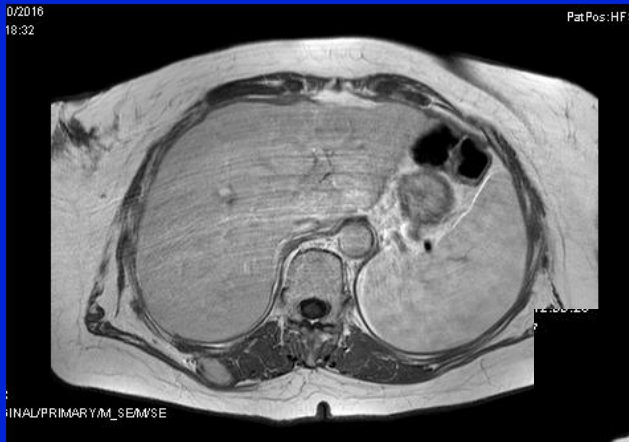Mar 2016



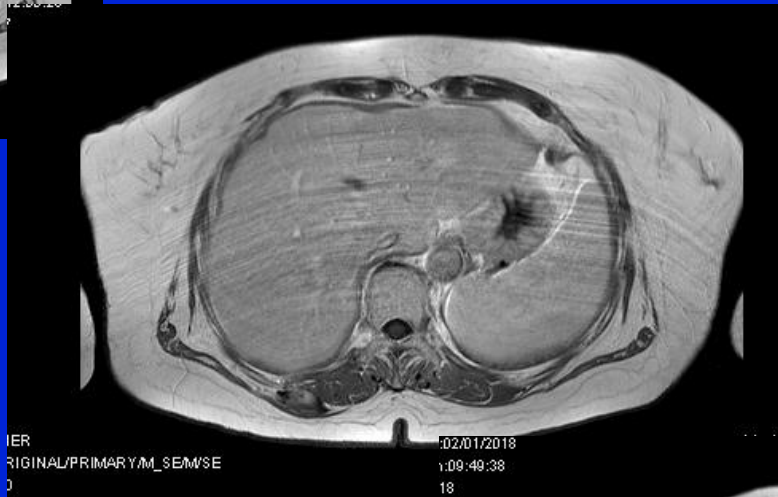
Giu 2016

**Female
61 yrs old
Trunk
Initial size: 8 cm**

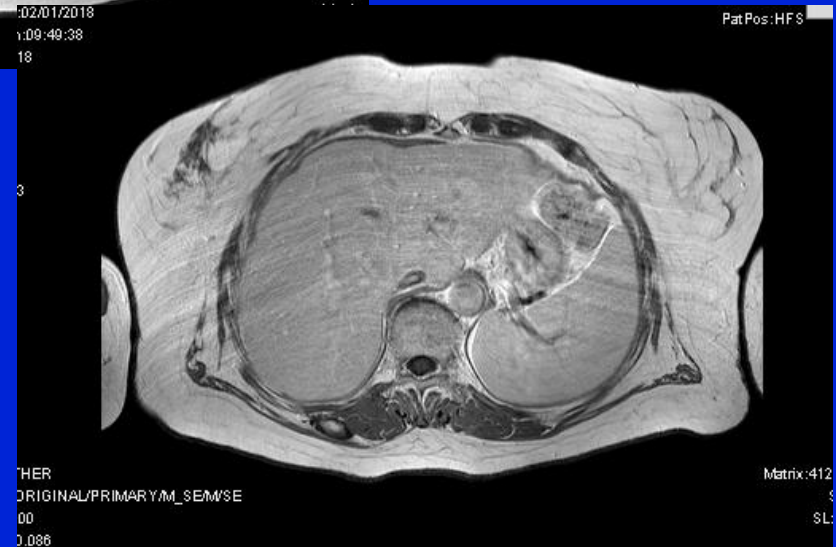



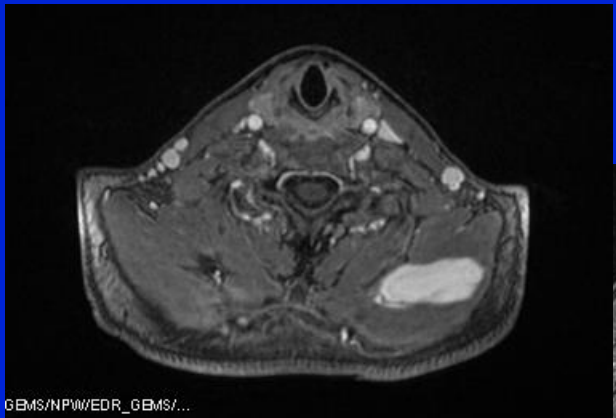Oct 2016



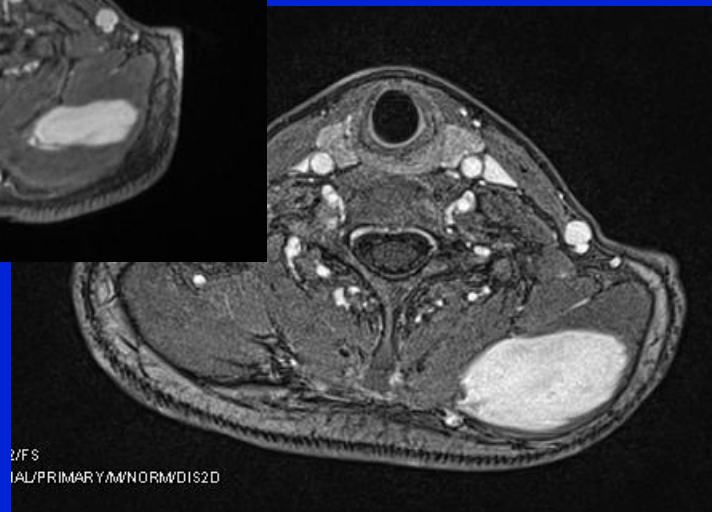
→ Apr 2017



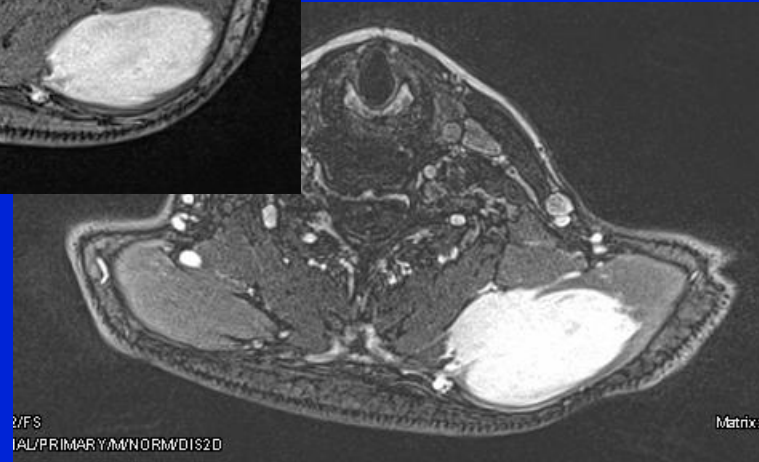
Jan 2018



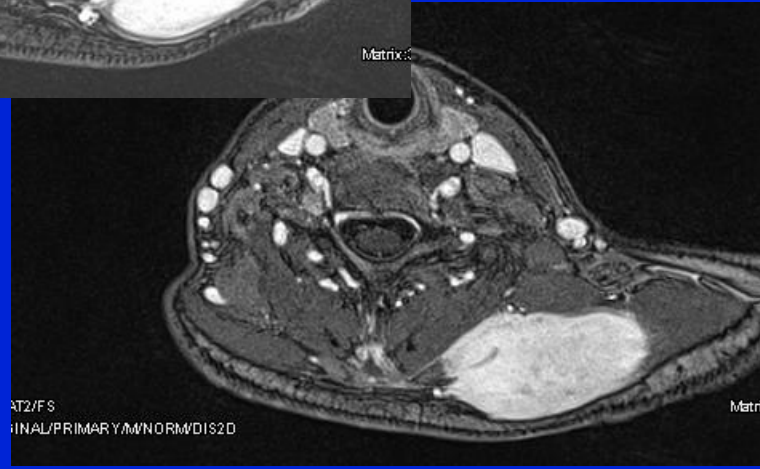Nov 2015



Feb 2016




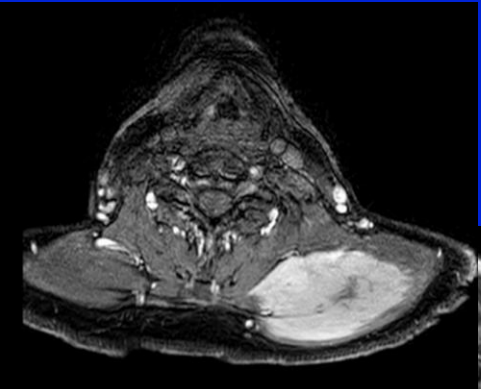
Mag 2016



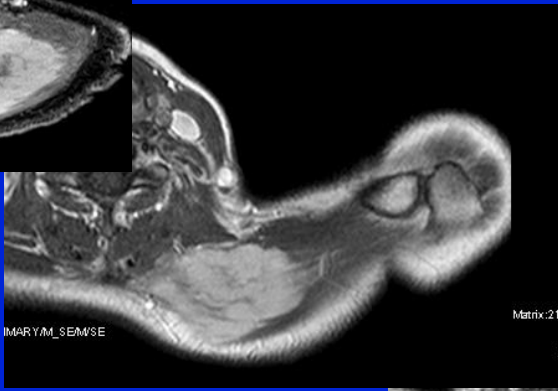Lug 2016

Female
48 yrs old
Trunk
Initial size: 4 cm

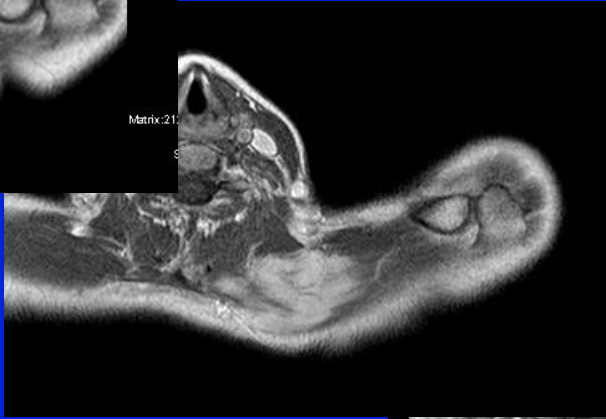




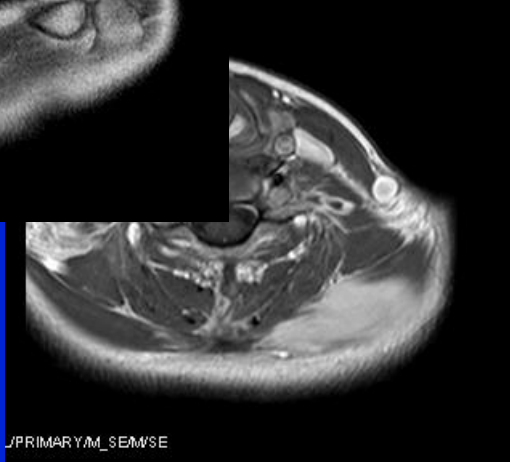
Nov 2016



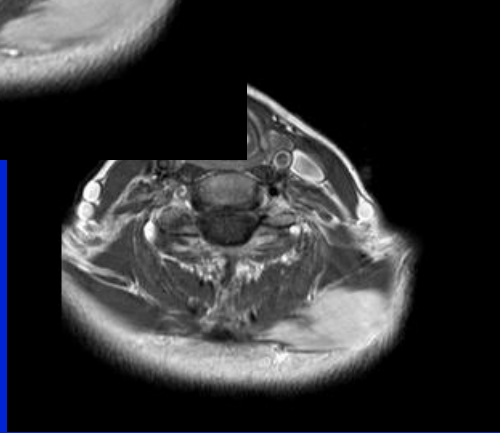
Mar 2017




Giu 2017

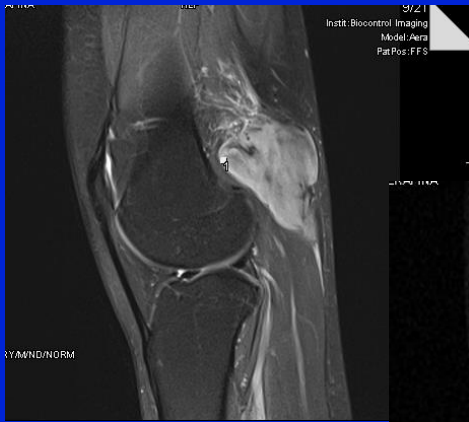


Dic 2017

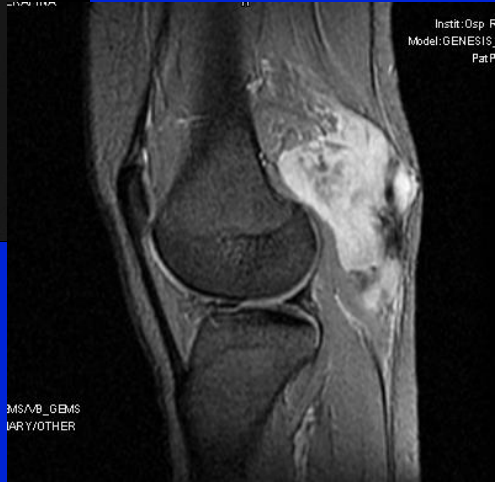

Giu 2018

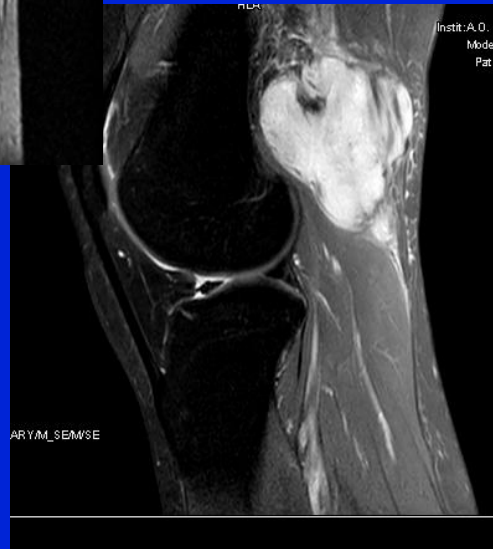



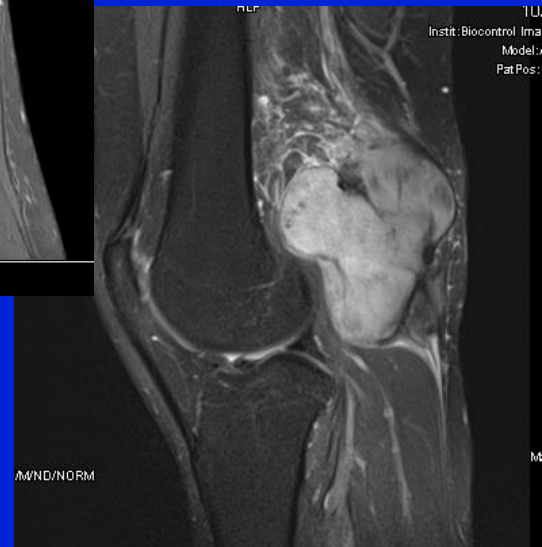
Feb 2015



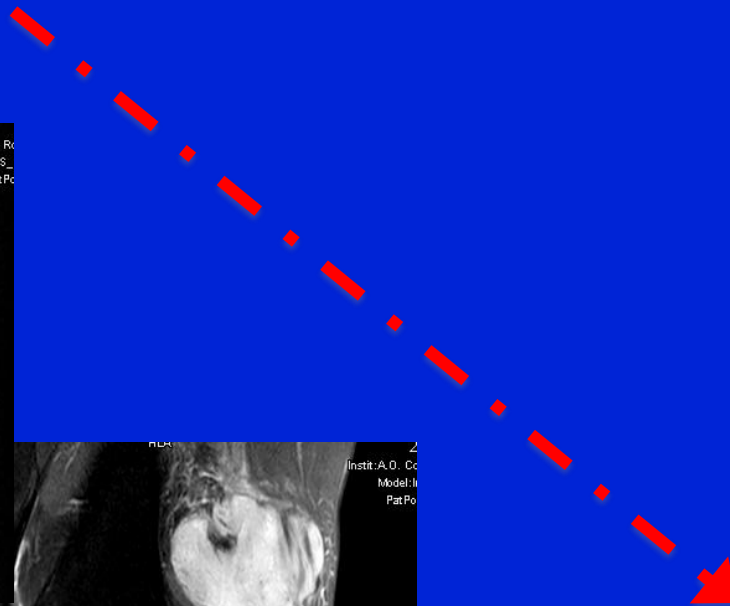
Giu 2015



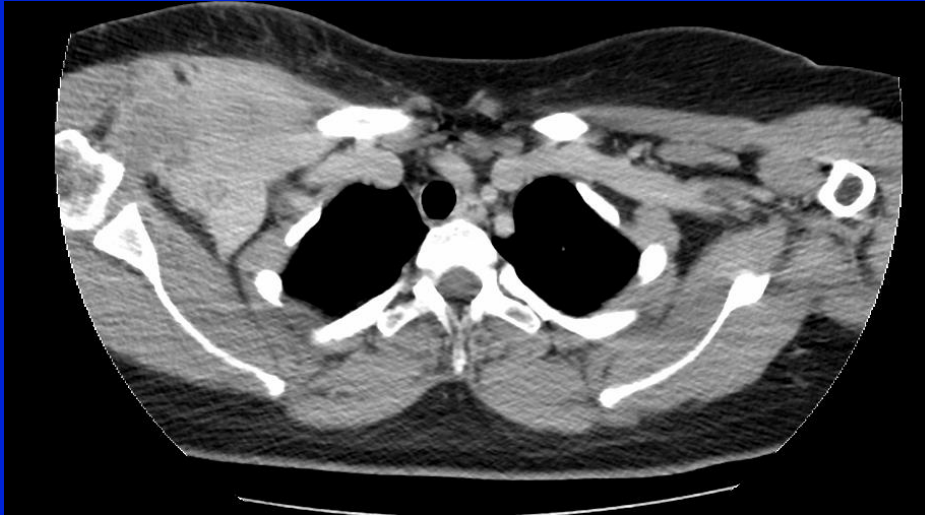
Oct 2015



Apr 2016



Female
24 yrs old
Extremity
Initial size: 6 cm
Time to active treatment:
14 months
Toremifene---MTX+VNB



Apr 2015

Female

18 yrs old

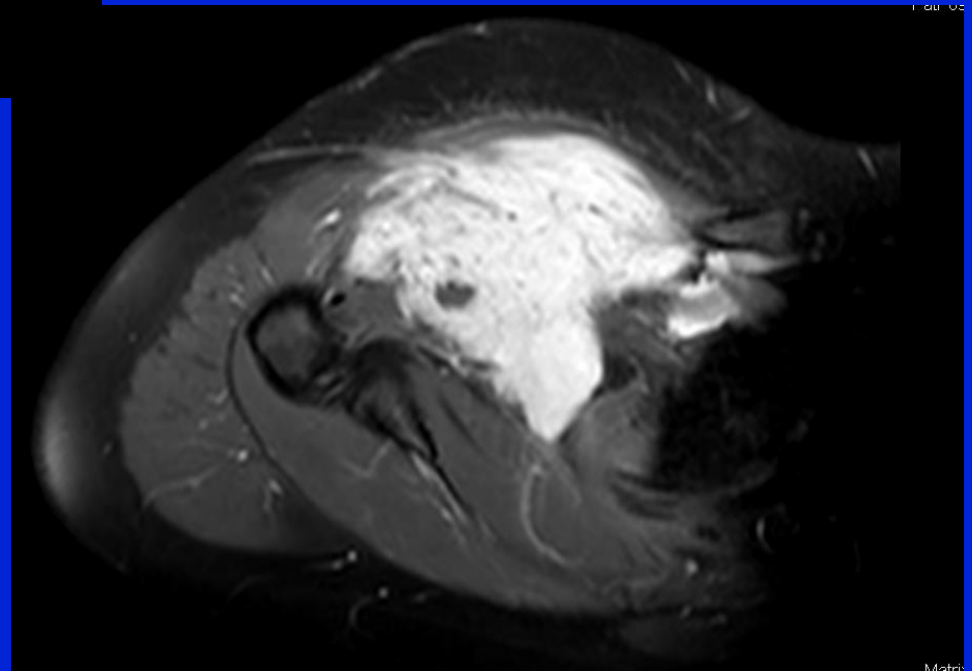
Trunk

Initial size 8 cm

Time to active treatment:

3 months

MTX+VNB



Lug 2015